

ARTICLE COVER SHEET

LWW—SCS

FLA, ERR

Article : scs20664

Creator : mjacinto

Date : Friday November 16th 2007

Time : 02:09:09

Article Title :

Number of Pages (including this page) : 6

Template Version : 2.0

Extraction Script is: sc_Extract_Xml

Multi-part Figure Marker is: sc_Multifig_Marker

Autopagination compliant

Original Article

Cheek Augmentation With Bio-Alcamid in Facial Lipoatrophy in HIV Seropositive Patients

Johannes Franz Hönig, MD, DMD, PhD

Goettingen, Germany

Lipoatrophy of the face in HIV seropositives are not susceptible to satisfactory correction by using single cosmetic surgery.

The limitation of the available filler products to augment and to correct the facial defects in facial lipoatrophy is mainly inherent in the amount of substance that can be implanted for the correction of lipoatrophy. Using Bio-Alcamid, which is an injectable, biocompatible, nontoxic, nonallergenic soft tissue filler designed to correct tissue deficits of various volume by intratissue administration, 9 nonrelated HIV seropositive patients with facial lipoatrophy (7 males and 2 females, age 43 ± 6 years) underwent cheek augmentation. From 7 ml to 16 ml of substance was injected each on both cheeks per application up to a maximum total of 25 ml. with a mean amount of $12 \text{ ml} \pm 4 \text{ ml}$. The median follow up time was 2 years. The results revealed that the corrections have remained essentially unchanged throughout the period of follow up. Bio-Alcamid maintained the form and blend with the surrounding tissues.

The surgical outcome was evaluated according to the analysis of photographs obtained before and after surgery, the analysis of pre- and postoperative measurements, and patients' self-judgment.

The level of satisfaction was significantly high: in 63 % of the cases, the result was judged to be excellent and in 32%, good. Only in 5% of the cases the result was considered poor.

The present study strongly suggests that Bio-Alcamid is suitable for the correction of remarkable defects of facial atrophy, otherwise treatable only

by surgery with myofascial free flaps. In addition, it permits a simplification of facial reconstruction and rejuvenation.

Key Words: Cheek augmentation, soft filler, endoprosthesis, Bio-Alcamid, facial rejuvenation, rhytidectomy

Facial lipoatrophy (LA) is characterized by fat loss and redistribution. Facial volume loss is the most obvious outward sign of LA because it alters the facial contours in the cheeks, temples, and orbits.¹⁻³ It is most commonly seen in patients with HIV on highly active antiretroviral therapy (HAART), which was introduced in the mid-1990s for the management of HIV, and is currently considered the mainstay therapy for HIV-infected patients.^{1,4}

However, the etiology of LA is likely multifactorial as underlying patient conditions, including duration and severity of HIV and increasing age, have also been found to contribute to its occurrence.^{1,5-7} The volume loss of LA can be very dramatic with some patients exhibiting no signs of facial fat.¹ As a result, many HIV-infected patients with associated LA suffer from psychological and lifestyle effects.⁸ The psychological impact may be severe.⁸ Thus, increases in facial volume and improvement in morphology is anticipated to reduce anxiety caused by LA in HIV-infected patients, and improve quality of life.⁴

Treatment approaches may be divided into three categories: 1) surgically-placed alloplastic, autologous, or synthetic implants; 2) injection of temporary fillers; or 3) injection of permanent fillers.² Several facial fillers have gained popularity as a means to restore the facial contour. Most are expensive, require multiple visits, and can produce scars. Temporary fillers require ongoing reapplication and permanent fillers may sag if lipoatrophy progresses and can lead to mismatching the host tissue texture.^{1,2}

Therefore, the ideal soft tissue augmentation material should be an inert, safe, noncancer-producing,

From the University Hospital and Medical School of Goettingen and Paracelsus Clinic Hanover, Germany, Plastic and Aesthetic Surgery.

Address correspondence and reprint requests to Dr. Johannes Franz Hönig, Full Clinical Professor, University Hospital and Medical School of Goettingen, Robert-Koch-Street 40, 37075 Goettingen, Germany; E-mail: info@professor-hoenig.de

Table 1. Amounts to be Injected According to Sites

Region	Amounts of Bio-Alcamid	
Naso-labial-fold	1 to 3 mL	2 mL \pm 0,6 mL
Cheeks	7 to 25 mL	12 mL \pm 4,3 mL
Lip line mL	1 to 2 mL	1 mL \pm 0,4 mL

stable, volume-filling material that is easy to use and remains in place over time and most importantly, is compatible with the host tissue. The latter request is important since it influences the ability of the filler to co-exist with the surrounding tissue, without stimulating the immune system or causing persistent inflammatory reactions, eventually leading to fibrosis.

The limitation of the available products is mainly inherent in the amount of substance that can be implanted for the correction of lipoatrophy.⁹ Interest in such compounds have led companies to venture ever further in the search for permanent substance that could replace soft tissue deficits perfectly and definitely, potentially via a simple injection.

AQ1

Among these fillers is a product called Bio-Alcamid R (Polymekon, Italy). It belongs to the group of hydorgels.¹⁰ Bio-Alcamid is an injectable non biodegradable hydrophobic cross-linked network of branched biopolymeric fluid with a reticulated structure derived from acrylic acid, made up of 96% sterile and apyrogenic water and 4% polyalkylamide gel.^{10,11} It is full of cross-links that remain impenetrable by any cell infiltration, including bacteria, and it is permeable only to ions and O₂.¹⁰⁻¹³ Bio-Alcamid is an injectable soft tissue filler designed to correct tissue deficits of various volume by intratissue administration.¹¹ It is biocompatible, nontoxic, nonallergenic, easily-injectable, and quickly removable.^{10,11}

After using this method to provide a natural and improved facial contour in nonrelated HIV seropositive patients for more than 3 years, we would like to share our experiences.

TECHNIQUE

The treatment was carried out under aseptic conditions, in a sterile field, and with a perioperative antibiotic cover. Bio-Alcamid was injected using 21–23G needle for facial wrinkles and 2–3 mm cannulae for bulker implants. It was instilled into a

single compartment without overfilling the superficial layers of the skin.

From 7 mL to 16 mL of substance was injected each on both cheeks per application up to a maximum total of 25 mL with a mean amount of 12 mL \pm 4 mL (Table 1). Injections were performed continuously and evenly from one side to the other in the deepest part of the sunken area at the subcutaneous level only.

PATIENTS

Nine nonrelated HIV seropositive patients with facial LA (7 males and 2 females, age 43 \pm 6 years, one of them has undergone a conventional face lift years before) underwent cheek augmentation. All patients underwent a thorough, individualized preoperative evaluation to establish a correct diagnosis, to evaluate asymmetries, to estimate the degree of LA.

The surgical outcome was evaluated according to the analysis of photographs obtained before and after surgery, the analysis of pre- and postoperative measurement, and patients' self-judgment.

RESULTS

The median follow up time was 2 years. Immediate healing was archived without complications or adverse reactions.

All patients healed uneventfully without any postoperative problems. The implantation of Bio-Alcamid caused an immediate modest inflammatory reaction in all patients which subsided within 24–36 hours. The edema, typical in postsurgery, slowly diminished, until vanishing after 2–3 days. Patients usually took up their social life again within 2 days. No migration or dislocation of the implants, no granulomas, no allergic response, and no kind of intolerance were observed. From the first control, the implants resulted soft, and the Bio-Alcamid appeared evenly distributed. The corrections have remained essential unchanged throughout the period of follow up. Bio-Alcamid has maintained the form and blend with the surrounding tissues.

The level of satisfaction was significantly high: in 63% of the cases, the result was judged to be excellent and in 32%, good. Only in 5% of the cases it was considered poor.

Tissue felt soft and the implants were uniformly distributed. In the light of the experience gained so far, the long-lasting results seem to be excellent. The

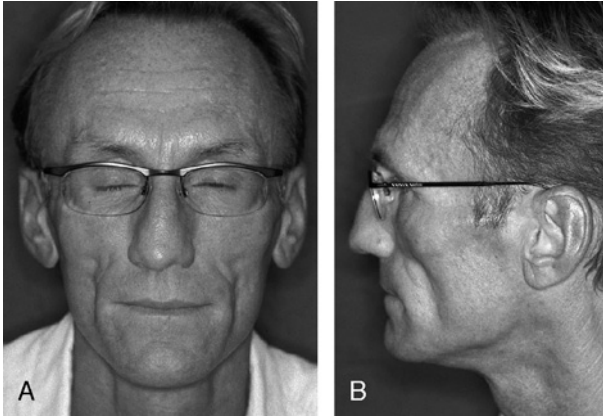


Fig 1 Preoperative frontal (A) and lateral (B) view of a patient with severe facial lipoatrophy related to antiretroviral therapy.

following examples (Figs 1–4) illustrate the indications and results.

DISCUSSION

Bio-Alcamid belongs to the group of hydrogels. Hydrogels are a class of polymers very similar to soft tissues for their high water content, the mechanical properties (very low modulus and elasticity), softness, oxygen permeability, and high biocompatibility.^{14,15}

Bio-Alcamid can be defined a sort of “endo-prosthesis”, suitable for soft tissue augmentation and for the correction of different tissue deficiencies, with a long-term safety and efficiency. It is a substance easy to inject and remove and which allows one to create volume. It does not migrate, and its safety

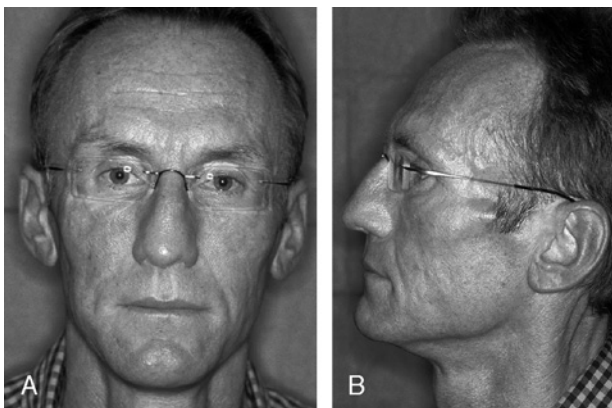


Fig 2 Postoperative view 2 years after Bio-Alcamid R injection of the cheeks and NLF. Frontal view (A) and lateral view (B). The corrections have remained essentially unchanged throughout the period of follow up.

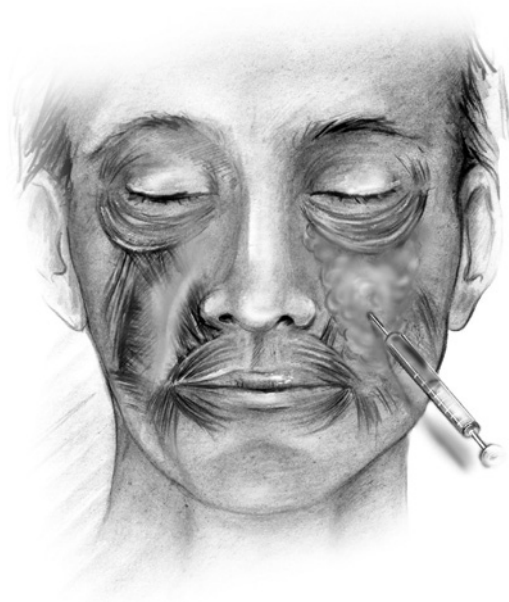

Fig 3 Schematic drawing of a facial lipoatrophy (right side) and the injection of a filler substance (left side); it illustrates on the left side of the face the area to be filled with Bio-Alcamid for correction of severe facial lipoatrophy. Note that the filling material is beneath the orbicularis muscle.

allows it to be suitable filler for the correction of slight and also very serious aesthetic defects of facial lipoatrophy.

Studies obtained by Lotti et al demonstrated that Bio-Alcamid becomes surrounded by a thin (0,02 nm), well-defined, and permanent capsule.^{14,16,17} They showed that after about 2 months, the activity of the fibroblasts included in the capsule gradually ceases, and thus the development of the capsule itself was blocked. The capsule, therefore, remained about 0,02 nm thick and, not receiving further stimuli, did not undergo further thickening or sclerosis.¹⁶

Further studies by Lotti et al¹⁶ have suggested a weak inflammatory reaction of cellular tissue surrounding the implant, and a slow and minimal gel resorption due to the infiltrating macrophages. But the macrophages were not responsible for any evident modification in the structure of Bio-Alcamid, and apparently do not cause gel resorption. The presence and number of CD68 macrophages in the upper perivascular dermis, far from gel implant, decreased significantly after four months. These cells are activated and responsible for the production of TNF-alpha. The fact that the TNF-alpha has a variable biological effect on fibroblast proliferation and that high concentrations inhibit growth is in accordance with the scars expression of fibroblasts found in

immune-histo-chemical studies done by Lotti et al¹⁶ in 2001. The lack of induction of fibroblast activation is also confirmed by focal expression of fibrogenic cytokine TGF-beta and the lack of expression of IL-6, which, as known, induces collagen synthesis by fibroblasts.¹⁶

The present study, along with those previously obtained,^{10-12,14-18} strongly suggests that Bio-Alcamid is suitable for the correction of remarkable defects like facial atrophy, otherwise treatable only by surgery with myofascial free flaps.¹⁸ In addition, it permits a simplification of facial reconstruction and rejuvenation.

AQ3

CONCLUSION

Bio-Alcamid is suitable for soft tissue augmentation and for correction of facial lipoatrophy, with a long term safety and efficiency.

The plasticity, the possibility of modeling, and the capacity to maintain the same texture as the tissue in which it is placed could almost lead one to overlook the other properties of this filler; it is permanent, removable, radiotransparent and nonsensitizing.

REFERENCES

1. Cofrancesco J Jr, Braun T. Report from the International Workshop on Adverse Drug Reactions and Lipodystrophy in HIV. *Hopkins HIV Rep* 2006;18:8-9
2. Jones D. Approaches to treatment of HIV facial lipoatrophy. *Skin Therapy Lett* 2005;10:5-7
3. Cofrancesco J Jr, Braun T, Martin CR. Management options for facial lipoatrophy. *AIDS Read* 2004;14(12):639-640. 645-650
4. Cattelan AM, Bauer U, et al. Use of polylactic acid implants to correct facial lipoatrophy in human immunodeficiency virus

AQ4

- 1-positive individuals receiving combination antiretroviral therapy. *AIDS Patient Care STDS* 2006;20:151-160
5. Sakuraoka K, Tajima S, Nishikawa T. Progressive facial hemiatrophy: report of five cases and biochemical analysis of connective tissue. *Dermatology* 1992;185:196-201
6. Mole B. Long - term treatment for lipoatrophy associated or not with infection using ePTFE implants and polyacrylamide gel. *Aesth Surg* 2005;25:561-570
7. Terenzi V, Leonardi A, Covelli E, et al. Parry-Romberg syndrome. *Plast Reconstr Surg* 2005;116(5):97-102
8. Echavez M, Horstman W. Relationship between lipoatrophy and quality of life. *AIDS Read* 2005;15:369-375
9. Caye N, Le Fourn B, Pannier M. Surgical treatment of facial lipoatrophy. *Ann Chir Plast Esthet* 2003;48:2-12
10. Pacini S, Ruggiero M, Cammarota N, et al. Bio-Alcamid, a novel prosthetic polymer, does not interfere with morphological and functional characteristics of human skin fibroblasts. *Plast Reconstr Surg* 2003;111:489-491
11. Pacini S, Ruggiero M, Morucci G, et al. Bio-Alcamid: a novelty for reconstructive and cosmetic surgery. *Ital J Anat Embryol* 2002;107:209-214
12. Claoue BL, Rabineau P. The polyalkylimide gel: experience with Bio-Alcamid. *Semin Cutan Med Surg* 2004;23:236-240
13. Orenstein A, Bar-Meir E. Bio-alkamid: avoiding the leak. *Plast Reconstr Surg* 2005;115:1789-1790
14. Formigli L, Zecchi S, Protopapa C, et al. Bio-Alcamid: an electron microscopic study after skin implantation. *Plast Reconstr Surg* 2004;113:1104-1106
15. Ramires PA, Miccoli MA, Panzarini E, et al. In vitro and in vivo biocompatibility evaluation of a polyalkylimide hydrogel for soft tissue augmentation. *J Biomed Mater Res B Appl Biomater* 2005;15(72):230-238
16. Lotti T, Cammarota N, Protopapa C. Immunohistochemical and ultrstructural evaluation of human tissue after subcutaneous injection of new filler Bio-Alcamid. *Polymekon Science Dosier* 2001;:28-31
17. Protopapa C, Sito G, Caporale D, et al. Bio-Alcamid in drug-induced lipodystrophy. *J Cosmet Laser Ther* 2003;5:226-230
18. Lutz BS, Toussaint S, Wei FC. Bilateral facial lipoatrophy secondary to connective tissue panniculitis treated with two microsurgically transplanted latissimus dorsi muscles. *Ann Plast Surg* 1998;40:302-307

AQ5

AQ6

AUTHOR QUERIES

AUTHOR PLEASE ANSWER ALL QUERIES

AQ1 = Please provide manufacturer city.

AQ2 = Please provide Figure 4.

AQ3 = Please confirm the placement of citation for reference 18 here.

AQ4 = Please list 3 authors before using “et al”.

AQ5 = Please check if captured correctly.

AQ6 = Please provide volume number.

END OF AUTHOR QUERIES

Author Reprints

For **Rapid Ordering** go to: www.lww.com/periodicals/author-reprints

Order

Journal of Craniofacial Surgery

 Lippincott
Williams & Wilkins
a Wolters Kluwer business

Author(s) Name _____

Title of Article _____

*Article # _____

*Publication Mo/Yr _____

*Fields may be left blank if order is placed before article number and publication month are assigned.

Quantity of Reprints _____ \$ _____

Covers (Optional) _____ \$ _____

Shipping Cost _____ \$ _____

Reprint Color Cost _____ \$ _____

Tax _____ \$ _____

Total _____ \$ _____

Reprint Pricing

100 copies = \$375.00

200 copies = \$441.00

300 copies = \$510.00

400 copies = \$585.00

500 copies = \$654.00

Covers

\$108.00 for first 100 copies

\$18.00 each add'l 100 copies

Reprint Color

(\$70.00/100 reprints)

Shipping

\$5.00 per 100 for orders shipping within the U.S.

\$20.00 per 100 for orders shipping outside the U.S.

Tax

U.S. and Canadian residents add the appropriate tax or submit a tax exempt form.

Use this form to order reprints. Publication fees, including color separation charges and page charges will be billed separately, if applicable.

Payment must be received before reprints can be shipped. Payment is accepted in the form of a check or credit card; purchase orders are accepted for orders billed to a U.S. address.

You may have included color figures in your article. The costs to publish those will be invoiced separately. If your article contains color figures, use Rapid Ordering www.lww.com/periodicals/author-reprints.

Prices are subject to change without notice.

Payment

MC VISA Discover American Express

Account # _____ / _____ / _____ Exp. Date _____

Name _____

Address _____ Dept/Rm _____

City _____ State _____ Zip _____ Country _____

Telephone _____

Signature _____

Quantities over 500 copies: contact our Pharma Solutions Department at **410.528.4077**

Outside the U.S. call **4420.7981.0700**

MAIL your order to:
Lippincott Williams & Wilkins
Author Reprints Dept.
351 W. Camden St.
Baltimore, MD 21201

FAX:
410.528.4434

For questions regarding reprints or publication fees,

E-MAIL:
reprints@lww.com

OR **PHONE:**
1.800.341.2258

Ship to

Name _____

Address _____ Dept/Rm _____

City _____ State _____ Zip _____ Country _____

Telephone _____

For **Rapid Ordering** go to: www.lww.com/periodicals/author-reprints